

Conservative Management of Trauma to Deciduous Maxillary Anterior Teeth: A Case Report

Anirudh Pathak¹, Jasneet Kaur², Mrigank Dogra³, Jaysshree Verma¹, Kanika Jain⁵

1-5- MDS Pedodontics and preventive Dentistry Himachal Dental College.

Correspondence to:
Dr. Anirudh Pathak, MDS Pedodontics and preventive Dentistry
Himachal Dental College.
Contact Us: www.ijohmr.com

ABSTRACT

Trauma to the maxillary primary anterior dentition is common in a pediatric dental setting. As they are complicated injuries, there is a need to establish priorities for an adequate emergency treatment of these lesions. Also, the primary dentition trauma presents special problems, and the management is often different as compared with permanent teeth. An appropriate emergency treatment plan is important for a good prognosis. This case report presents successful management of luxation of deciduous anterior teeth by means of splinting.

KEYWORDS: Deciduous dentition, Trauma, Luxation, Splinting

INTRODUCTION

From birth, a child is exposed to traumatic episodes, which, depending on the energy of the impact, can result in injuries which may range in severity from minor problems to life-threatening cases. The prevalence of traumatic injuries in the 0–6-year segment varies from 11 to 30%^{1,2} and the most common type of injury seen is the luxation of the anterior teeth.³ Kenwood and Seow⁴ reported that in children < 7 years old, more than 30% have experienced trauma to their primary dentition. These injuries occur most often to anterior teeth⁵ and males are injured more frequently than females.⁶ Unfortunately, the morphology and location of these teeth make them susceptible to a range of traumatic injuries.⁷ Trauma to these teeth in addition to effecting aesthetics, phonetics and functional activities, has a psychological impact both on the child and the parents.⁸

The leading causes of most dental trauma are accidental falls and violence. In addition, as children become involved in sports at a young age, failure to wear a properly

fitted mouthguard while engaging in sports activities has become another significant factor in increasing the risk of dental trauma.⁶ Patients can present with a wide variety of injuries, ranging from damage to the tooth itself, such as crown or root fractures, to injuries to the supporting periodontal structure, including luxations and avulsions. In contrast to injuries of the permanent anterior teeth—where fractures are the most prevalent type of injury—the majority of injuries to the primary anterior dentition are luxations.⁹

Oral luxation affects mainly the maxillary central incisors. Horizontal force directed to the labial aspect of

the crown displaces it palatally pushing the root apex labially and away from the developing permanent tooth bud. When the child has normal relations between the dental arches (i.e. the incisal edge of the mandibular incisors are in contact with the palatal aspect of the maxillary incisors), oral displacement of the crown will create occlusal interference. Luxation also causes rupture of the gingival fibers and the periodontal ligament (PDL). Detachment of gingival fibers allows invasion of oral microorganisms along the root surface and infection of the PDL. In addition, the delicate labial bone plate often fractures concomitant with haemorrhage and swelling of the upper lip.

Proper diagnosis, treatment planning and follow up are critical to assure a favourable outcome of traumatic dental injuries. One of the critical phases of the treatment is the splinting or stabilization of the affected teeth. It has been shown that fixation of only one week is enough to achieve the clinical healing of repositioned teeth¹⁰. Apart from esthetic and hygienic components, demands on tooth fixation techniques also include ease of construction and removal and the use of devices which allow slight movement of the fixed teeth¹⁰. Current evidence supports short-term, non-rigid splints for splinting of luxated teeth.

The purpose of this paper is to present a conservative treatment of two cases of oral luxation of maxillary primary incisors and their follow-up evaluation.

CASE REPORT

Case 1

A six year old boy reported to the Department of Pedodontics and Preventive Dentistry of Himachal Dental

How to cite this article:

Pathak A, Kaur J, Dogra M, Verma J, Jain K. Conservative Management of Trauma to Deciduous Maxillary Anterior Teeth: A Case Report. *Int J Oral Health Med Res* 2016;3(1):206-209.

College, Sundernagar, about 2 hours after fall from the bicycle resulting in dental trauma. (Figure 1) His medical history was uneventful with no known allergies. He did not lose consciousness nor did he vomit following the injury. Extra-oral examination revealed no disturbances in the temporo-mandibular joint. Swelling of the lower lip was observed. Intra-oral examination revealed hematoma of the lower lip, soft tissue lacerations, and palatal displacement of both maxillary primary central incisors into cross bite relations with the opposing mandibular teeth. Despite this, the child could close his molars into normal occlusion. A periapical radiograph of the premaxilla presented shortened images of both central incisors with a wide periapical radiolucent area indicating that the apices of the primary teeth were pushed labially, away from the developing permanent successors. (Figure 2)

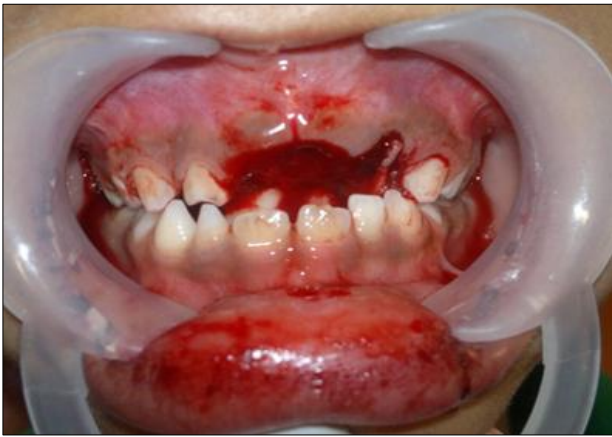

Fig. 1 Clinical view showing maxillary incisors in cross-bite, shortly after injury.

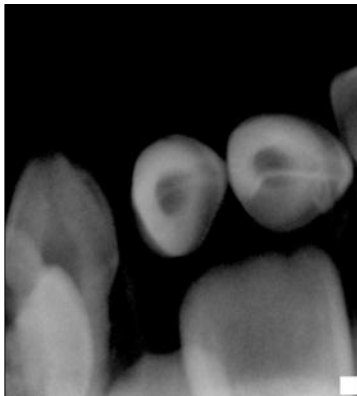


Fig. 2 Intra-oral periapical radiograph after the injury.

The treatment consisted of repositioning the teeth and bone fragments by finger pressure, with the patient under local anesthesia. A periapical radiograph was taken to ensure that the teeth had been correctly positioned in the socket. The teeth were splinted from canine to canine with composite resin and a 0.7mm orthodontic wire. (Figure 3) Instructions for strict oral hygiene were given and antibiotics and analgesics were prescribed.

Patient was kept on weekly recall. After three weeks, when the mobility was markedly reduced, the splint was

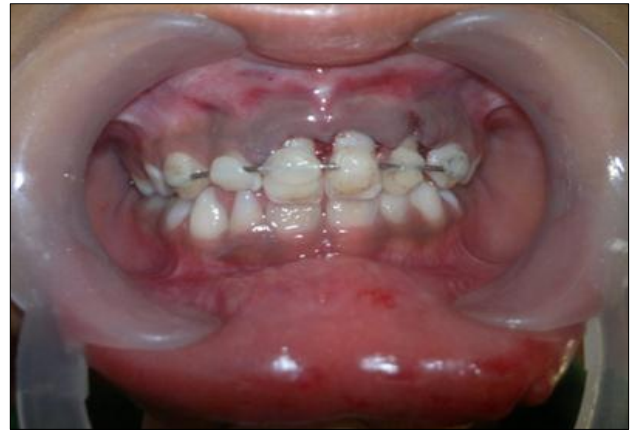

Fig.3 Clinical view showing the repositioned teeth with light curing resin and orthodontic wire

removed. The teeth were present in a good occlusal relationship. (Figure 4) On the following recall examinations, teeth presented physiologic mobility, with no sensitivity to percussion. Surrounding soft tissues were intact and the patient did not report any pain or discomfort.

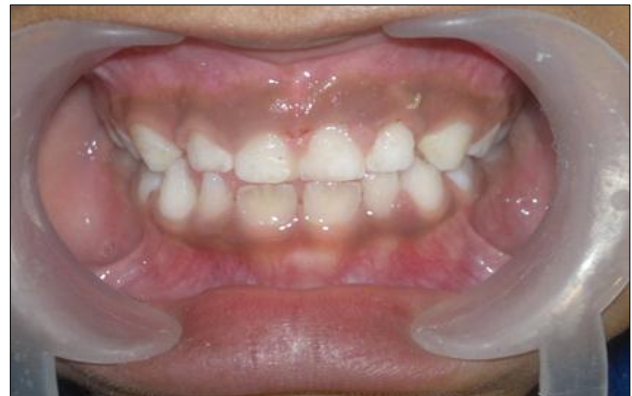

Fig.4 Clinical view after the removal of splint.

Case 2

A five year old girl reported to the Department of Pedodontics and Preventive Dentistry of Himachal Dental College, Sundernagar, H.P. with a history of fall while playing 5-6 hours back. (Figure 5) On clinical

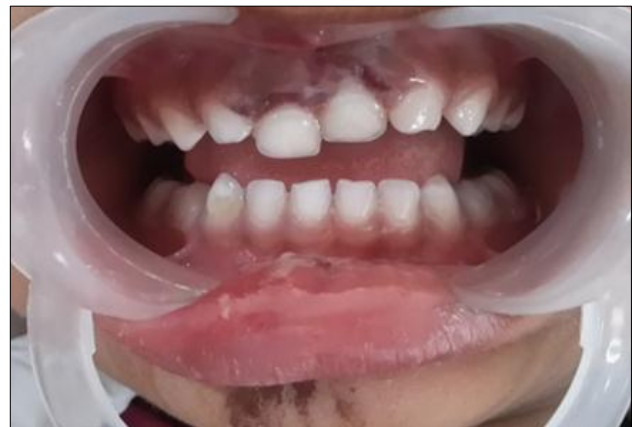

Fig 5. Clinical view shortly after trauma

examination, laceration of chin and lips was present, as well as laceration of the maxillary labial mucosa at the maxillary central incisors, which had a lateral luxation and hypermobility was seen. Periapical radiographic examination did not show root fracture or any other injuries involving other teeth. There was no relevant medical history.

The treatment protocol consisted of careful repositioning of the teeth under local anaesthesia, and as the repositioned teeth often have a tendency to migrate from their position, a flexible splint was applied for 2-3 weeks. (Figure 6) Patient was instructed to maintain good oral hygiene and was given a course of antibiotics and analgesics.

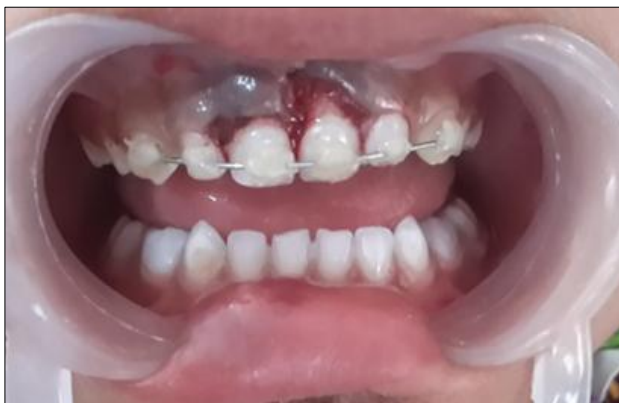

Fig 6. Repositioned and splinted teeth.

Three weeks after the injury, after clinical and radiographic examination of periodontal and bone healing, the splint was removed. The soft tissues had healed, and a good occlusion was established. (Figure 7)

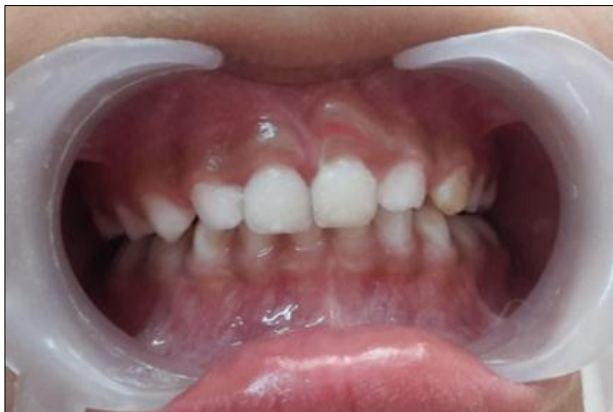

Fig 7. Occlusion after the removal of splint.

DISCUSSION

The cases presented in this paper are one of the commonest injuries occurring in primary dentition. Such injuries involve the supporting tissues i.e. periodontal ligament, gingival fibers, and bone, and the vitality of the pulp. Orally luxated incisors cannot return spontaneously to their normal alignment when interference exists between the maxillary and mandibular teeth, and it

requires intervention.

The time interval elapsed since injury is very important because it influences the choice of treatment.¹¹ According to Andreasen et al.¹¹, repositioning of the dislocated teeth is more difficult after 48 h of the injury. Delayed repositioning may be difficult probably due to a blood clot organized in the socket. After luxation injury, immediate reposition and stabilization of the teeth in their anatomically correct positions are essential to optimize healing of the periodontal ligament and neurovascular supply, while maintaining esthetic and functional integrity. Splinting with orthodontic wire and composite resin for stabilization of traumatically displaced teeth for 2-4 weeks, as performed in the present case, has been reported to lead to satisfactory results, since it allows for physiologic mobility and easy cleansing.¹²

The child's age at the time of injury is an important factor affecting the operator's decision on the suitable approach. The younger the child, the greater the risk for damages to the succedaneous permanent tooth, and the more severe the defect may be.¹¹ It has been shown that injuries to primary teeth may affect permanent teeth and cause hypo-calcification even at a later age.¹³ Also, the age of the child determines the level of cooperation that he/she will show. It seems reasonable, however, that a young child seen by a dentist following dental trauma is apprehensive and does not cooperate.

CONCLUSION

It is impossible to completely prevent accidents that might result in dental injuries especially in cases of children, but their associated complications can be avoided by adequate treatment and follow-up. The present cases provide a conservative alternative to extraction for severely injured primary incisors. Splinting, good oral hygiene, and antibacterial therapy may preserve the injured teeth until natural exfoliation.

REFERENCES

1. Cunha RF, Pugliesi DM, Mello Vieira AE. Oral trauma in Brazilian patients aged 0-3 years. *Dent Traumatol* 2001;17: 210 - 2.
2. Hargreaves JA, Cleaton-Jones PE, Roberts GJ, Williams S, Matejka JM. Trauma to primary teeth of South African pre-school children. *Endod Dent Traumatol* 1999;15: 73 - 6.
3. Osuji OO. Traumatized primary teeth in Nigerian children attending University Hospital: the consequences of delays in seeking treatment. *Int Dent J* 1996;46: 165 - 70.
4. Kenwood M, Seow WK: Sequelae of trauma to the primary dentition. *J Pedod* 13:230-38, 1989.
5. Kapala J, Frankl S: A preliminary investigation of traumatized primary anterior teeth. *Alpha Omegan* 64:165-83, 1971.
6. Gutmann JL, Gutmann MS. Cause, incidence, and prevention of trauma to teeth. *Dent Clin North Am* 1995;39:1-13.
7. Kania MJ, Keeling SD, McGorray SP, Wheeler TT, King GK. Risk factors associated with incisor injury in

- elementary schoolchildren. *Angle Orthod* 1996;66:423–32.
8. Alonge OK, Narendran S, Williamson DD. Prevalence of fractured incisal teeth among children in Harris County, Texas. *Dent Traumatol* 2001;17:218–21.
 9. Andreasen JO: Challenges in clinical dental traumatology. *Endod Dent Traumatol* 1:45-55, 1985.
 10. Oikarinen, K.: Tooth splinting: a review of the literature and consideration of the versatility of a wire-composite splint. *Dental Traumatology*, 6: 237–250,1990.
 11. Andreasen JO, Andreasen FM, Andersson L. Textbook and color atlas of traumatic injuries to the teeth. 4th ed. Oxford: Blackwell; 2007.
 12. American Academy on Pediatric Dentistry Council on Clinical Affairs. Guideline on management of acute dental trauma. *Pediatr Dent* 2008-2009;30:175-183
 13. Brin, I.; Ben-Bassat, Y.; Zilberman, Y.; Fuks, A : Effect of trauma to the primary incisors on the alignment of their permanent successors in Israelis. *Community Dent Oral Epidemiol.* 16:104-108, 1988.

Source of Support: Nil
Conflict of Interest: Nil